

Fixation of intertrochanteric femur fractures using the SIGN intramedullary nail augmented by a lateral plate in a resource-limited setting without intraoperative fluoroscopy: assessment of functional outcomes at one-year follow-up at Juba Teaching Hospital

Mapuor M.M. Areu^a, Ericka P. von Kaeppler^b, Brian Billy Madison^a, Akau A. Aguto^a, James Alphones^a, Lewis G. Zirkle^c, Saam Morshed^b, David W. Shearer^{b,*}

Abstract

Objectives: The incidence of hip fracture is high and increasing globally due to an aging population. Morbidity and mortality from these injuries are high at baseline and worse without prompt surgical treatment to facilitate early mobilization. Due to resource constraints, surgeons in low-income countries often must adapt available materials to meet these surgical needs. The objective of this study is to assess functional outcomes after surgical fixation of intertrochanteric femur fractures with the Surgical Implant Generation Network (SIGN) intramedullary nail augmented by a lateral SIGN plate.

Design: Prospective case series

Setting: Juba Teaching Hospital, Tertiary Referral Hospital for South Sudan

Participants: Adult patients with intertrochanteric hip fractures

Intervention: SIGN nail augmented by a lateral plate

Main Outcome Measurements: Primary outcome was hip function as measured by a modified Harris Hip Score (mHHS) at 1-year after surgery. Secondary endpoints were the occurrence of reoperation or infection at 1-year after surgery.

Results: Thirty patients were included, 16 (53%) men and 14 (47%) women, with a mean age of 62 years. Fractures were classified as AO/OTA Type 31A1 in 12 (40%) patients, 31A2 in 15 (50%) patients, and 31A3 in 3 (10%) patients. Mean mHHS at 1-year was 75.10±21.2 with 76% categorized as excellent or good scores. There was 1 (3%) infection and 2 (7%) reoperations.

Conclusions: The SIGN nail augmented by a lateral plate achieved good or excellent hip function in the majority of patients with intertrochanteric hip fractures. This may be a suitable alternative to conventional implants for hip fracture patients in low-resource settings to allow mobilization.

Keywords: hip fracture, implant alternative, low- and middle-income countries, surgical implant generation network intramedullary nail, surgical implant generation network lateral FX plate, Sudan

LZ is president and founder of SIGN Fracture Care International. DS serves as vice president of SIGN Fracture Care International. No other authors have any conflicts of interests to disclose.

This article was partially funded by an OTA Award, based on the merit of the submission.

^a Department of Orthopedic and Traumatology, University of Juba (UJU), Juba, South Sudan, ^b Department of Surgery, University of California San Francisco, San Francisco, CA, ^c Department of Orthopedics, Kadlec Regional Medical Center, Richland, WA, USA.

* Corresponding author. Address: 2550 23rd Street, Building 9, 2nd Floor San Francisco, CA 94110. E-mail: address: david.shearer@ucsf.edu (David W. Shearer).

Copyright © 2021 The Authors. Published by Wolters Kluwer Health, Inc. on behalf of the Orthopaedic Trauma Association.

This is an open access article distributed under the terms of the Creative Commons Attribution-Non Commercial-No Derivatives License 4.0 (CCBY-NC-ND), where it is permissible to download and share the work provided it is properly cited. The work cannot be changed in any way or used commercially without permission from the journal.

OTAI (2021) e133

Received: 1 June 2020 / Received in final form: 17 February 2021 / Accepted: 2 April 2021

Published online xx xx 2021

<http://dx.doi.org/10.1097/OI9.000000000000133>

1. Introduction

Hip fractures represent a significant orthopedic burden around the world and are estimated to reach an incidence of at least six million fractures per year by 2050.^[1] Extracapsular hip fractures, those occurring distal to the hip joint capsule and sometimes called intertrochanteric fractures,^[2] are among the most frequently occurring fractures in elderly people, often resulting from low energy trauma secondary to osteoporosis.^[3] With the worldwide increase in life expectancy, the incidence of these fractures is increasing dramatically,^[4] with the largest increase predicted to occur in developing countries.^[5] These fractures are classified into three groups according to the AO/OTA classification system:^[6,7]

- 1) 31A1 simple pertrochanteric
- 2) 31A2 multifragmentary pertrochanteric
- 3) 31A3 intertrochanteric (reverse oblique).

Morbidity and mortality from these injuries are high at baseline and worse without prompt surgical treatment to

facilitate early mobilization and rehabilitation.^[8–12] Successful treatment requires reduction and stable fixation, thus internal fixation has emerged as the gold standard for the treatment of intertrochanteric fracture.^[13,14] Internal fixation also reduces complications related to prolonged bed rest and immobilization and longer hospitalization stays, thus decreasing morbidity and mortality rates.^[13–16] Providing stable fixation by internal fixation necessitates the careful selection of appropriate implants suited to fracture characteristics, including stability.^[14] Extramedullary devices, such as the sliding hip screw (SHS), are acceptable for stable fractures, but intramedullary devices, such as cephalomedullary nails, are recommended for unstable fractures^[14] and have become the implant of choice for many extracapsular hip fractures.^[17]

Intramedullary nails are significantly more expensive than sliding hip screws,^[17] potentially limiting their use in resource-constrained environments. Despite this documented cost-effectiveness of sliding hip screws in many parts of the world, they are often not affordable, nor widely available in many low- and middle-income countries (LMICs). Further, both sliding hip screws and cephalomedullary nails require intraoperative fluoroscopy and radiolucent operating tables, which are often unavailable in many LMICs.^[18] The choice of appropriate implant is, thus, often limited in LMICs where implant costs can be prohibitively expensive and intraoperative imaging is often not available. The need for affordable implants that can be inserted without fluoroscopy in LMICs has driven innovation and adaptation of available implants to meet these local needs. One such innovation is the application of the widely used surgical implant generation network (SIGN) interlocking IM nail, that does not require fluoroscopy,^[18] augmented by a lateral SIGN plate to stabilize intertrochanteric femur fractures. This technique utilizes the IM nail for load sharing and the lateral plate as a tension band and is gaining in popularity in LMICs.

The SIGN standard nail, donated at no cost to participating hospitals, has been widely used over the last 2 decades for the fixation of many types of long bone fracture in LMICs,^[19,20] as it allows for insertion without image intensifiers.^[18] More recently, the SIGN hip construct (SHC) was designed to address these same challenges in the treatment of proximal hip fractures.^[21,22] However, the SHC is not as widely available as the standard SIGN nail. By adding a lateral plate to the standard nail, it is hypothesized that the construct may be more similar to the proximal femoral nails commonly used in high-income countries (HICs). Unlike the implants commonly used in HICs, insertion of a SIGN nail does not require removal of a large amount of bone from either the trochanteric entry site or femoral head due to the smaller size of both the proximal body of the nail and the screws inserted into the femoral head. This makes the implant safer to insert without fluoroscopy compared to a sliding hip screw or cephalomedullary designs used in HICs. While the standard SIGN nail is not a fixed angle device, the addition of the lateral plate prevents screws from collapsing into varus in addition to acting as a tension band across the lateral extent of the fracture. The plate utilized in the study is also manufactured and donated by SIGN and has been titled the “HV plate”. It is a unique design that most closely resembles a 4.5 mm reconstruction plate in terms of stiffness and ease to contour. This implant combination may serve as an acceptable alternative in LMICs where even the previously studied SHC may not be available.

To date, no prior studies have evaluated the effectiveness of the SIGN nail augmented by a lateral plate for hip fractures. The objective of this study was to assess functional outcomes after

surgical fixation of intertrochanteric femur fractures with the SIGN intramedullary nail augmented by a lateral SIGN plate (IMN+P).

2. Methods

2.1. Study design and setting

This prospective case series was conducted at Juba Teaching Hospital, a tertiary referral hospital for South Sudan. Enrollment was conducted from July 2018 to July 2019.

2.2. Ethical approval

Ethical approval was obtained from the University of Juba Research Ethical Committee Board.

2.3. Study population

Skeletally mature adult patients (greater than 18 years of age) with intertrochanteric femur fractures who were treated with the SIGN nail and a lateral plate and were being seen for 1-year follow-up were included in this study. Patients were excluded if they met any of the following criteria:

- (1) femoral neck fracture,
- (2) subtrochanteric femur fracture
- (3) pathologic femur fracture

In accordance with standard international and regional research ethics, eligible patients were instructed about study protocols and asked to provide informed consent in order to enroll in the study.

2.4. Surgical technique

2.4.1. Preparation. All patients received a dose of prophylactic antibiotics before the surgical incision. Spinal anesthesia was routinely used, with general anesthesia utilized only when indicated and spinal anesthesia was not possible. Patients were placed in a lateral decubitus position with a pillow placed between the thighs. The affected limb was prepped free to allow for manipulation to achieve reduction.

2.4.2. Approach and reduction. An open reduction was performed in all cases. The incision was made centered on the fracture site and extended 6 cm distally to accommodate plate fixation. The incision was extended proximally over the junction between the anterior third and the posterior two-thirds of the greater trochanter. The incision was then curved slightly posteriorly approximately 5 cm along the expected trajectory of the nail entry proximally. The fracture was then reduced under direct visualization with manual traction. (Fig. 1A) *No fluoroscope nor traction table was used.* Reduction was maintained using 2 bone reduction clamps. The first bone clamp was placed from anterior either around the lesser trochanter or the calcar if the lesser trochanter was detached from the proximal fragment. Manual traction and flexion of the distal fragment were used when necessary to account for the deforming forces of the iliopsoas muscle. A second clamp was placed from the posterior aspect of the greater trochanter to the anterior cortex to reduce the proximal extension of the fracture in the greater trochanter.

2.4.3. Nail insertion. The entry site location was determined based on the integrity of the greater trochanter. If the greater trochanter was intact, the entry point was made at the tip of the greater trochanter at the junction between the posterior one-third and anterior two-thirds. If the greater trochanter was fractured,

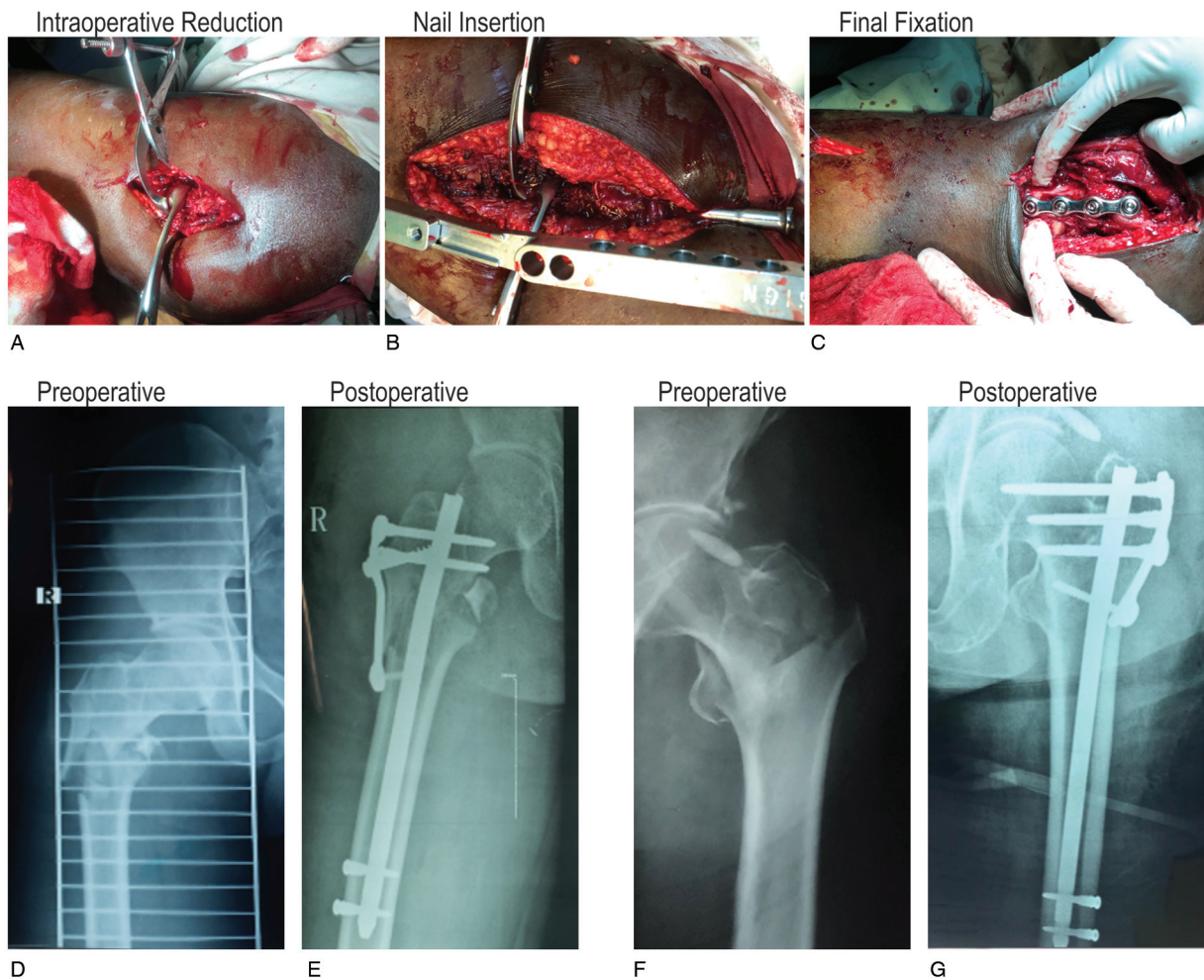


Figure 1. Surgical Technique. Panel A illustrates the intraoperative reduction of an intertrochanteric fracture using 2 bone-holding clamps. Panel B illustrates the insertion of the SIGN standard nail with the target arm. Panel C illustrates lateral augmentation of the nail with a plate for additional fixation of the intertrochanteric fracture. Panel D shows a preoperative and Panel E shows a postoperative radiograph of intertrochanteric femur fracture treated with an intramedullary nail augmented with lateral plate (IMN+P) in a 24-year-old male injured in a road traffic accident. Panel F shows a preoperative and Panel G shows a postoperative radiograph of an intertrochanteric femur fracture treated with IMN+P in a 115-year-old male injured in a fall from standing height.

the entry point was at the piriformis fossa. A curved awl was used to create the entry hole. The nail is solid therefore no guidewire was used. A small sharp hand reamer was used to sequentially ream the femoral canal while visualizing and maintaining fracture reduction at all times. Reaming was increased in increments of 1 mm until chatter. A nail diameters 2 mm smaller than the largest reamer used was selected. The entry site was overreamed to accommodate for the proximal nail bend. The SIGN standard nail was then assembled on the back table and the surgeon personally ensured that the slots in the nail aligned with the target arm. The target arm was then removed, and the nail was introduced (Fig. 1B). Gentle taps were used to fully seat the nail approximately 2 to 3 mm proud at the tip of the greater trochanter. It is critical to ensure that the fracture remains reduced during this step. When implant position and fracture reduction were satisfactory, the target arm was introduced, and distal interlocking was performed using the jig as previously described for the SIGN nail.^[18–20]

2.4.4. Proximal interlocking and plate application. A 4 to 6-hole HV plate was contoured to fit the anatomy of the greater trochanter. The length of the plate was selected to ensure fixation

distal to the fracture. The first proximal interlocking screw was placed through the HV plate using the target arm, leaving at least 1 screw hole on the plate proximally to provide another point of fixation. It is not necessary for all of the proximal SIGN interlocking screws to pass through the plate as the plate can be locked independently using cortex and cancellous screws in the lateral cortex and the greater trochanter. A second interlocking screw was placed using the target arm. The proximal holes in the HV plate were filled with 6.5mm screws bypassing the nail targeting either the femoral head or lesser trochanter depending on the fracture configuration. Distally 3.5mm screws were inserted bicortically around the nail. The wound was closed in layers.

2.4.5. Postoperative care. Postoperatively patients received intravenous antibiotics for 3 days and switched to oral antibiotics on the fourth postoperative day for 1 week. Patients were mobilized using an assistive device on postoperative day 1 and advised to partial weight bear for 6 weeks.

2.5. Data collection

Participants were enrolled and all data collected at the 1-year postsurgical follow-up visit. A study questionnaire was adminis-

tered to collect participant demographic data including age and sex. AO/OTA fracture classification^[6,7] and mechanism of injury were collected for each patient. Modified Harris Hip Score (mHHS), a patient-reported outcome score ranging from 0 to 100 that evaluates pain and function, was used to assess function.^[2,3] mHHSs were categorized as excellent, good, fair, and poor according to previously published thresholds.^[24] Patients were evaluated for infection by the treating surgeon. Any incidence of reoperation was recorded.

2.6. Data analysis

Data were analyzed using Statistical Package for Social Scientists (SPSS) software version 24 (IBM Corp., Armonk, NY, USA). Descriptive statistics were used to describe measured variables. For continuous variables, means, standard deviations, and ranges were reported. For categorical variables, counts and proportions were reported. Unpaired student's *t* test was used to compare means of continuous variables between subgroups. Fisher exact test and 1-way ANOVA were used to compare proportions of categorical variables between subgroups.

3. Results

Thirty patients with intertrochanteric femur fractures who were treated with the SIGN nail and a lateral plate were enrolled, 16 (53%) males and 14 (47%) females. The mean age was 62 years (24–115 years) (Table 1). Twenty-one patients (70%) were injured in a fall from standing height (FFS) and 9 (30%) were injured in a road traffic accident (RTA). Patients injured by RTA were younger and more frequently male compared to FFS. All patients had closed fractures. Twelve (40%) patients had AO/OTA type 31A1 fractures, 15 (50%) had type 31A2 fractures, and 3 (10%) had type 31A3 fractures (Table 1).

3.1. Hip function

The average mHHS was 75.1 (SD 21.2) and ranged from 10 to 91. The average mHHS was higher for patients who sustained fractures in RTA (90.0) than for those injured in FFS (68.8, *P* = .0092). The scores were excellent or good in 23 (77%) cases at 1 year, including 100% of RTA patients and 67% of FFS patients (*P* = .071) (Table 2). Mean mHHS at 1-year was higher in patients who did not have limb deformity (*P* = .0020) nor limb

Table 1
Patient demographics and injury characteristics by the mechanism of injury.

	All	RTA	FFS
N	30	9 (30%)	21 (70%)
Age, mean (range)	63 (24–115)	45 (24–70)	71 (39–115)
Gender			
Male	16 (53%)	9 (100%)	7 (33%)
Female	14 (47%)	0 (0%)	14 (67%)
AO/OTA Classification			
31A1	12 (40%)	4 (44%)	8 (38%)
31A2	15 (50%)	4 (44%)	11 (52%)
31A3	3 (10%)	1 (11%)	2 (10%)
Side Injured			
Right	21 (70%)	8 (89%)	13 (62%)
Left	9 (30%)	1 (11%)	8 (38%)
Limb Shortening	9 (30%)	2 (22%)	7 (33%)

FFS = Fall from standing height, RTA = road traffic accident.

Table 2
Modified Harris Hip Score (mHHS).

	All	RTA	FFS
Mean (range)	75.1 (10–91)	90 (88–91)	68.8 (10–91)
Excellent (81–100)	16 (53%)	9 (100%)	7 (33%)
Good (61–80)	7 (23%)	0 (0%)	7 (33%)
Fair (41–60)	5 (17%)	0 (0%)	5 (24%)
Poor (≤ 40)	2 (7%)	0 (0%)	2 (10%)

FFS = Fall from standing height, RTA = road traffic accident.

shortening (*P* = .0032) on presentation. Mean mHHS was not different between AO/OTA fracture types (*P* = .9319, 1-way ANOVA).

3.2. Occurrence of infection and reoperation

There were 2 cases (6.7%) that underwent reoperation: 1 for infection 6 weeks postoperatively in an OTA 31A3 fracture, and the other was converted to hemiarthroplasty due to nonunion in an OTA 31A2 fracture. Both cases of reoperation occurred in patients who sustained fractures from FFS. There were no other cases of infection or nonunion in the series (Table 3) with 97% (29) of patients achieving union by 1 year.

4. Discussion

Intertrochanteric fractures are common and represent a significant disease burden around the world. Successful treatment requires anatomic reduction and stable fixation to allow for early mobilization and rehabilitation.^[13,14] Prompt surgical management, often with internal fixation, reduces complications associated with prolonged immobilization like deep vein thrombosis, pulmonary embolism, respiratory tract infections, and bedsores.^[13–16] Adequate fixation requires careful selection of appropriate implants,^[14] yet the choice of appropriate implant is especially complicated in LMICs where intraoperative fluoroscopy often is not available,^[18] and implants may be prohibitively expensive to patients.^[25] Here we describe a novel technique using a standard SIGN nail with lateral plate augmentation that is a viable alternative to high-cost implants that require fluoroscopy for the treatment of intertrochanteric fractures in LMICs.

In this study of 30 patients with intertrochanteric fractures treated with IMN+P, we show that the majority of patients achieve Excellent or Good hip function one year after surgery. The hip function measured in this study falls within the ranges observed in other studies of IM nailing for intertrochanteric femur fractures, with one recent systematic review and meta-analysis reporting Harris Hip Scores ranging from 67 to 92.^[26] Further, we report acceptably low rates of infection and reoperation with this approach. A Cochrane review of intramedullary nails for intertrochanteric fractures described infection rates of up to 7% and revision rates up to 10%.^[27] We report infection and reoperation rates of 3% and 7%, respectively.

Table 3
Occurrence of infection and reoperation.

Variable	No. of patients (%)
Infection	1 (3.3%)
Reoperation	2 (6.7%)

While the SHC is another recently developed system aimed at addressing these challenges related to treating proximal hip fractures in LMIC,^[21,22] the SHC is not as widely available and accessible as SIGN intramedullary nails. As such, the SHC has been slow to become widely adopted, including at Juba Teaching Hospital. The standard SIGN nail augmented with a lateral SIGN plate is a viable and available alternative to the SHC for the treatment of proximal femur fractures. The complication rates observed in this study were comparable to rates reported with the SHC. The SHC has been reported to have a 1.4% infection rate, comparable with our observed 3% infection rate, and a 4.2% nonunion rate, comparable with our observed 3% nonunion rate.^[21,28]

This study is limited by being conducted at a single center in Juba, South Sudan. Though we believe this setting reflects the challenges faced by many LMICs including the lack of intraoperative fluoroscopy and access to higher-cost implants, additional study at other sites is needed to generalize results beyond Juba. Additionally, the inclusion of both high energy and low energy trauma patients provided a heterogeneous study population that may limit overall conclusions or mask population-specific conclusions. Additional study of each group individually may be warranted.

As a patient-reported outcome, the mHHS is prone to, and may be limited by, subjectivity though it has been previously validated for use in proximal femur fractures.^[29] Due to inconsistent radiograph quality, we were limited to binary assessments and were unable to assess for granular quantitative data such as radiographic measurement of healing and angular deformity which have been reported in other case series. Finally, there was no comparator group against which to assess the outcomes following treatment with this new surgical approach. Future direct comparison with the SHC may provide useful evidence for the noninferiority of this more widely available implant strategy.

This study is the first to describe the novel technique and report outcomes using the SIGN intramedullary nail system with the lateral plate for AO 31A1-3 intertrochanteric fractures. The high functional scores and low complication rates at one year suggest this technique may be a sustainable, low-cost option for treating these injuries in austere environments where fracture care is particularly challenging due to the lack of intraoperative fluoroscopy and radiolucent operating tables. While this technique is not likely to replace conventional techniques in HICs where reverse obliquity and traditional intertrochanteric fractures have distinct, standardized treatment protocols, it may nonetheless have significant impact by expanding access to surgery and early mobilization to patients who would otherwise be treated nonoperatively in low-income countries.

5. Conclusion

The SIGN nail augmented by a lateral plate achieved good or excellent hip function in the majority of patients with intertrochanteric hip fractures. This may be a suitable alternative to conventional implants for hip fracture patients in low-resource settings to allow early mobilization.

References

- Socci AR, Casemyr NE, Leslie MP, et al. Implant options for the treatment of intertrochanteric fractures of the hip. *Bone Joint J.* 2017;99-B:128–133.
- Parker MJ, Das A. Extramedullary fixation implants and external fixators for extracapsular hip fractures in adults. *Cochrane Database Syst Rev.* 2013;(2):CD000339.
- Asif N, Ahmad S, Qureshi OA, et al. Unstable intertrochanteric fracture fixation – Is proximal femoral locked compression plate better than dynamic hip screw. *J Clin Diagn Res.* 2016;10:RC09–RC13.
- Gullberg B, Johnell O, Kanis JA. World-wide projections for hip fracture. *Osteoporos Int.* 1997;7:407–413.
- Elffors L. Are osteoporotic fractures due to osteoporosis? Impacts of a frailty pandemic in an aging world. *Aging (Milano).* 1998;10:191–204.
- Müller ME, Nazarian S, Koch P, et al. *The Comprehensive Classification of Fractures of Long Bones.* Berlin, Germany: Springer-Verlag; 1990.
- Meinberg E, Agel J, Roberts C, et al. *Fracture and Dislocation Classification Compendium—2018.* *J Orthop Trauma.* 2018;32:S1–S10.
- Mattisson L, Bojan A, Encosn A. Epidemiology, treatment and mortality of trochanteric and subtrochanteric hip fractures: data from the Swedish fracture register. *BMC Musculoskelet Disord.* 2018;19:369.
- Uzoigwe CE, Burnand HG, Cheesman CL, et al. Early and ultra-early surgery in hip fracture patients improves survival. *Injury.* 2013;44:726–729.
- Leer-Salvesen S, Engesæter LB, Dybvik E, et al. Does time from fracture to surgery affect mortality and intraoperative medical complications for hip fracture patients? *Bone Joint J.* 2019;101-B:1129–1137.
- Al-Ani AN, Samuelsson B, Tidermark J, et al. Early operation on patients with a hip fracture improved the ability to return to independent living: a prospective study of 850 patients. *JBJS.* 2008;90:1436–1442.
- Borges FK, Bhandari M, Guerra-Farfan E, et al. Accelerated surgery versus standard care in hip fracture (HIP ATTACK): an international, randomised, controlled trial. *Lancet.* 2020;395:698–708.
- Yu J, Zhang C, Li L, et al. Internal fixation treatments for intertrochanteric fracture: a systematic review and meta-analysis of randomized evidence. *Sci Rep.* 2015;5:18195.
- Kaplan K, Miyamoto R, Levine BR, et al. Surgical management of hip fractures: an evidence-based review of the literature. II: intertrochanteric fractures. *JAAOS.* 2008;16:665–673.
- Siu AL, Penrod JD, Boockvar KS, et al. Early ambulation after hip fracture: effects on function and mortality. *Arch Intern Med.* 2006;166:766–771.
- Harper CM, Lyles YM. Physiology and complications of bed rest. *J Am Geriatr Soc.* 1988;36:1047–1054.
- Evaniew N, Bhandari M. Cochrane in CORR®: intramedullary nails for extracapsular hip fractures in adults (Review). *Clin Orthop Relat Res.* 2015;473:767–774.
- Liu MB, Ali SH, Haonga BT, et al. Surgical Implant Generation Network (SIGN) Fin nail versus SIGN standard intramedullary nail for distal diaphyseal femur fractures treated via retrograde approach. *Injury.* 2019;50:1725–1730.
- Sekimpi P, Okike K, Zirkle L, et al. Femoral fracture fixation in developing countries: an evaluation of the Surgical Implant Generation Network (SIGN) intramedullary nail. *J Bone Joint Surg Am.* 2011;93:1811–1818.
- Usoro AO, Bhashyam A, Mohamadi A, et al. Clinical outcomes and complications of the surgical implant generation network (SIGN) intramedullary nail: a systematic review and meta-analysis. *J Orthop Trauma.* 2019;33:42–48.
- Roth J, Goldman B, Zirkle L, et al. Early clinical experience with the SIGN hip construct: a retrospective case series. *SICOT-J.* 2018;4:55. doi:10.1051/sicotj/2018050.
- Zirkle LGJ, Shearer D, Roth J. SIGN hip construct surgical technique and early clinical experience. *Tech Orthop.* 2009;24:258–264.
- Ramisetty N, Kwon Y, Mohtadi N. Patient-reported outcome measures for hip preservation surgery—a systematic review of the literature. *J Hip Preserv Surg.* 2015;2:15–27.
- Prajapati P, Prajapati V, Patel P, et al. Functional Outcome of Unstable Intertrochanteric femur fracture treated with intramedullary nailing. *J Res Med Den Sci.* 2016;4:266.
- Gellman RE. Fracture care challenges in the austere and humanitarian environments. *Curr Trauma Rep.* 2016;2:100–105.
- Ju J, Zhang P, Jiang B. Hip replacement as alternative to intramedullary nail in elderly patients with unstable intertrochanteric fracture: a systematic review and meta-analysis. *Orthop Surg.* 2019;11:745–754.
- Queally JM, Harris E, Handoll HH, et al. Intramedullary nails for extracapsular hip fractures in adults. *Cochrane Database Syst Rev.* 2014;9:CD004961.
- Haonga BT, Eliezer EN, Makupa JE. SIGN hip construct: achieving hip fracture fixation without using an image intensifier. *EAJ.* 2016;10:7–10.
- Vishwanathan K, Akbari K, Patel AJ. Is the modified Harris hip score valid and responsive instrument for outcome assessment in the Indian population with pertrochanteric fractures? *J Orthop.* 2018;15:40–46.