

See discussions, stats, and author profiles for this publication at: <https://www.researchgate.net/publication/363374781>

Lower back musculoskeletal hydatid cyst: a rare presentation in a South Sudanese patient

Article in *South Sudan Medical Journal* · September 2022

DOI: 10.4314/ssmj.v15i3.8

CITATIONS

2

READS

37

4 authors, including:



Justin Bruno Tongun
University of Bergen

20 PUBLICATIONS 249 CITATIONS

SEE PROFILE



Joseph Lako
University of Juba, Juba City, South Sudan.

20 PUBLICATIONS 36 CITATIONS

SEE PROFILE

Lower back musculoskeletal hydatid cyst: a rare presentation in a South Sudanese patient

Lodu Swokiri N Kuju,¹ Kenneth Lado Sube,^{2,3,4} Justin Bruno Tongun^{2,3} and Joseph Daniel Lako^{3,4,5}

1. Kapoeta State Hospital, Eastern Equatoria State, South Sudan
2. School of Medicine, University of Juba, South Sudan
3. Health and Social Sciences Research Institute - South Sudan (HSSRI-SS)
4. South University of Medicine, Science and Technology (SUMST), South Sudan
5. School of Applied and Industrial Sciences, University of Juba, South Sudan

Correspondence:
Kenneth Lado Sube
ladolojuan@gmail.com

Submitted: March 2022

Accepted: April 2022

Published: August 2022

Citation: Kuju et al. Lower back musculoskeletal hydatid cyst: a rare presentation in a South Sudanese patient. *South Sudan Medical Journal* 2022;15(3):110-113 © 2022 The Author (s) **License:** This is an open access article under [CC-BY-NC](https://creativecommons.org/licenses/by-nc/4.0/) DOI: <https://dx.doi.org/10.4314/ssmj.v15i3.8>

ABSTRACT

Echinococcosis (hydatidosis) remains a crucial public health concern in areas of endemicity including South Sudan. It affects mostly liver and lungs but rarely musculoskeletal system. A female, aged 75 years, presented to Kapoeta State Hospital, with a three years' history of a painless mass on her back, gradual onset. There was no history of trauma, pain or fever. On examination there was a mass of 8cm x 5cm, soft, non-tender and lobulated on the right lower back above the gluteal region with intact skin. Imaging investigations (ultrasound, X-ray, CT scan) were not available. A provisional diagnosis of a lipoma was made. Surgery was done successfully and a hydatid cyst was found and removed. There were no post-operative complications. She was discharged on the next day with oral albendazole (400mg), twice a day for 28 days. Six months later, the patient was seen with no complains or recurrence. In endemic areas hydatid cysts should be considered in the differential diagnosis of any cystic swelling or lump. In low resource countries, incorporation of health education to school curriculum will play a key role in reducing incidence or prevalence of the disease.

Key words: Echinococcosis, lump, excision, hydatid cyst.

INTRODUCTION

Cystic echinococcosis, known as hydatidosis or hydatid disease, is an important public health concern especially in endemic areas in Africa, Asia, Middle East, Mediterranean countries, Australia and South America.^[1] Out of the four causative organisms, *Echinococcus granulosus* and *Echinococcus multilocularis* are the commonest causing hydatid and alveolar cysts respectively. Humans are infected by the ingestion of eggs passed either by dogs, sheep, goats, cattle and camels. These eggs then form oncospheres that which pass through the intestinal mucosa thence being distributed via the blood to the liver and other structures where they develop into embryos. These can either form cysts or they spread to other parts of the body via blood.^[2]

The liver (75%) and lungs (15%) are the most commonly affected organs^[3,4] as they filter blood, preventing the parasite from entering the systemic circulation.^[5] The musculoskeletal system is less often affected with prevalence ranging from 0.7-3 %^[6,7] to 7.2 %.^[8] This is due to high levels of lactic acid which creates a hostile environment for the parasite to survive.^[3] Our case report is to alert clinicians to the need to consider the possibility of hydatid disease especially in endemic areas. Such a mass requires careful surgical excision.

CASE PRESENTATION

A 75-year-old lady presented to the outpatient department, complaining of a painless mass on her back of three years duration. The lump started as a small mass that gradually increase in size. There was no history of trauma, pain or fever.




Figure 1. Some of vesicles and ruptured cysts from the patient with presumed lipoma.

On examination there was a mass of 8cm x 5cm, soft, non-tender and lobulated on the right lower back above the gluteal region with intact skin. Further investigations were not available. A clinical diagnosis of lipoma was made and surgery under general anaesthesia was planned after a full explanation to the patient. A complete blood count was normal. A hydatid cyst was revealed and meticulously dissected from the surrounding tissues. It was removed completely with some ruptured cysts (Figure 1).

The cavity was irrigated with hypertonic saline, and povidone iodine 10% solution (Figure 2). A drainage tube was placed, cavity tissues approximated with absorbable sutures and the wound closed with non-absorbable sutures. After 24 hours, the drain was removed. She was discharged on the next day with oral albendazole (400mg), twice a day for 28 days. Six months later, she was reviewed and found healthy without signs of recurrence.

DISCUSSION

The World Health Organization has recognized human echinococcosis as one of the neglected tropical diseases.^[9] It is endemic in South Sudan with a prevalence of 3.5%.^[10] Molecular studies^[11] indicated that the main strain is a camel genotype G6 of *E. canadensis* which is more infective to animals and human. A prospective study on 117 patients referred to Juba Teaching Hospital,^[12] indicated that most of the cases (98%) were from Pibor (65%), Kapoeta (18%) and Lafon (15%) with different patterns of symptomatology.

These ranged from abdominal mass (76%), breast mass (5%), neck swelling (3%) and other masses (9%). The liver and lungs (78%) were the most commonly affected organs.^[12] Most (93%) of the patients were successfully managed surgically while 7% were medically managed due to the dissemination of the disease to multiple organs.^[12]

Surgical success is partly dependent on the careful

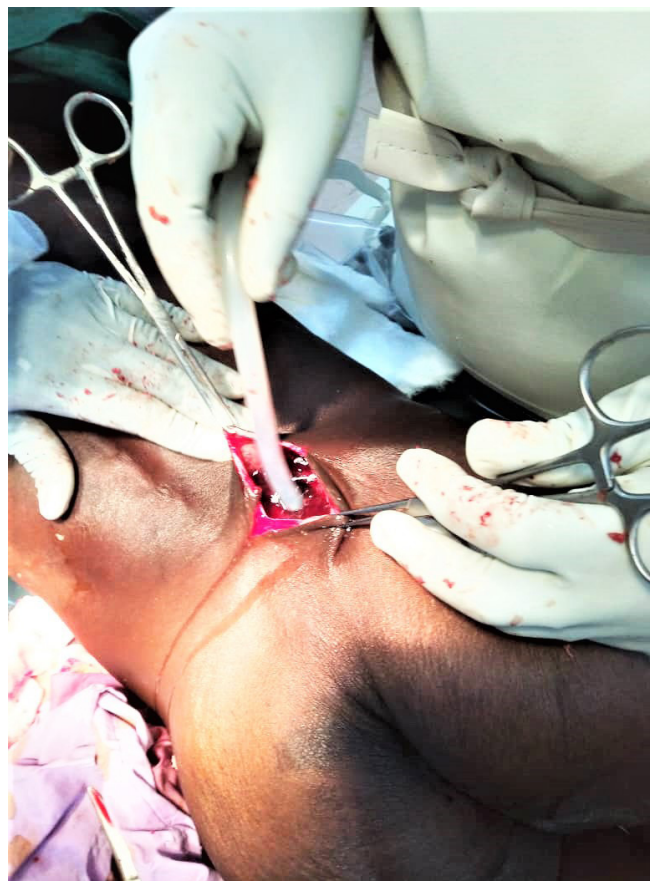

Figure 2. The wound being washed and aspirated with a sucker using normal saline for toileting the cavity.

dissection at surgery. However, secondary hydatid cysts^[13] can occur without such care. Surgery is the most favoured procedure to treat hydatid disease. This involves careful and complete removal of the cyst with vigorous irrigation of the cyst cavity with scolicidal agents like povidone iodine 10%, hypertonic saline 15-30%, formalin 10% and chlorhexidine gluconate 5%.^[14] Each needs exposure time of 10 minutes. Hydrogen peroxide 3% and silver nitrate with exposure time to tissue of 15 and 5 minutes respectively can be used. Avoidance of cysts rupture is important in order to avoid complications such as anaphylaxis. All these solutions will reduce recurrence. Patients need to be followed up for possible recurrence.

To diagnose hydatid cysts, ultrasonography, CT scan and MRI play a key role. However, in low resource countries like South Sudan and particularly in rural health facilities, clinical and epidemiological knowledge is of a paramount importance. Any lump or swelling in endemic areas must include hydatid cyst in the differential diagnosis.

We feel that "One health" approach could be useful in reducing the burden of echinococcosis in human as well as in livestock in communities living in endemic areas. The approach deals with the concept that health of

people is related to the health of the animals as well as environment.^[15] There are several definitions. One Health Global Network: “One Health recognizes that the health of humans, animals and ecosystems are interconnected”. While the US Centers for Disease Control and Prevention and the One Health Commission is: ‘One Health is defined as a collaborative, multisectoral, and transdisciplinary approach—working at the local, regional, national, and global levels—with the goal of achieving optimal health outcomes recognizing the interconnection between people, animals, plants, and their shared environment’.

This approach recognizes that animals and humans are mostly infected by the same microorganisms as they share the same ecosystem. Thus, usage of one sector in prevention or control or elimination of a particular infectious disease won't succeed.

CONCLUSION

In endemic areas, any cystic swelling or lump should include hydatid cyst in the differential diagnosis. Imaging facilities are helpful. The gold standard of management is careful surgical excision of the mass. In low resource countries, incorporation of health education about echinococcosis in the school curriculum should play a key role in reducing the incidence of the disease. “One Health” approach could be cost effective in reducing the burden of the disease in both humans and livestock. This requires collective efforts of Ministries of Health, animal resources and livestock, and other concern agencies to work together and establish a national Echinococcosis control programme.

Competing interests: The authors declare that they have no competing interests.

Authors' contributions: LN did the surgery and prepared the photos and the history of the patient, KS did the literature review, writings and compiled the manuscript, JB and JL did proofreading. All authors read and agreed to the final manuscript.

Acknowledgement: We thank the patient for allowing us to publish this case.

References

1. Kayaalp C, Dirican A, Aydin C. Primary subcutaneous hydatid cysts: a review of 22 cases, *Int J Surg* .2011;9(2):117-21. Epub 2010 Oct 25. <https://www.sciencedirect.com/science/article/pii/S1743919110004632>
2. Pinar P et al. Hydatid disease from head to toe. *Radiographics*. 2003; 23: 475–494. DOI: <https://dx.doi.org/10.1148/rg.232025704>
3. Malik P, Singh K. Primary hydatid cyst of intercostal muscles: a rare entity, *Int J Sci Rep*. 2016 Jul;2(7):165-167. DOI: <http://dx.doi.org/10.18203/issn.2454-2156.IntJSciRep20162167>
4. Basarir K, Saglik Y, Yildiz Y, Yetis T, Cebesoy O, Primary muscular hydatidosis mimicking soft tissue tumour: a report of five cases, *J Orthop Surg (Hong Kong)* 2008 Dec;16(3):368-72. <https://doi.org/10.1177%2F230949900801600321>
5. Tuna S, Duymus TM, Yanik HS, Durakbasa MO, Mutlu S, Erdem S. Hydatid cyst of biceps brachii associated with peripheral neuropathy, *Int J Surg Case Rep*. 2015; 8:150–153. DOI: <https://doi.org/10.1016/j.ijscr.2015.02.008>
6. Akjouj S, El Kettani N, Raissouni Z, Semlali S, Aziz N, Amil T et al. Quel est votre diagnostic. *Journal de Radiologie*. 2006; Jul 1:87(7-8):989-91.
7. Guthrie JA, Lawton JO, Chalmers AG. Case report: the MR appearances of primary intramuscular hydatid disease. *Clin Radiol*. 1996 May;51(5):377-9.
8. Soltany S, Hemmati HR, Toussy JA, Nazifi H, Alibakhshi A, Toosi PA. Evaluation of Musculoskeletal Hydatid Cyst Cases in Terms of Clinical Manifestations, Method of Dealing, Treatment, and Recurrence. *Open Access Maced J Med Sci*. 2020 Mar 25; 8(E):99-104. <https://doi.org/10.3889/oamjms.2020.4274>
9. Hotez PJ, Fenwick A, Savioli L, Molyneux D. Rescuing the bottom billion through control of neglected tropical diseases. *Lancet*. 2009 May 2;373(9674):1570-5.
10. Magambo JK, Hall C, Zeyle, et al. Prevalence of human hydatid disease in southern Sudan. *Afr J Health Sci*. 1996;3(4):154–6.
11. Omer, R.A., et al., A molecular survey of cystic echinococcosis in Sudan. *Vet. Parasitol*. 2010; DOI: <https://dx.doi.org/10.1016/j.vetpar.2010.01.004>
12. Lado, D.K .Cystic Hydatid Disease in Southern Sudan. *The Annals of African Surgery* June 2008; 2

13. Thomas RW, Ellis-Owen R, Winson D. Secondary peritoneal hydatidosis, the challenges of echinococcal disease in South Sudan: a case report. *Pan African Medical Journal*. 2015; 20:15 DOI: <https://dx.doi.org/10.11604/pamj.2015.20.15.5809>
14. Ahmed ME, Hassan OA, Khalifa AKA et al. Echinococcosis in Tambool, Central Sudan: a knowledge, attitude and practice (KAP) study. *Int Health* 2018;10:490–494 DOI: <https://dx.doi.org/10.1093/inthealth/ihy055>
15. Zinsstag J, Mackenzie JS, Jeggo M, et al. Mainstreaming One Health. *EcoHealth* 2012;9,107–110, DOI: <https://dx.doi.org/10.1007/s10393-012-0772-8>