

See discussions, stats, and author profiles for this publication at: <https://www.researchgate.net/publication/362002353>

# Double uterus in young women delivered by Caesarean Section: five cases from South Sudan and Ethiopia

Article in Sudan Medical Journal · July 2022

CITATIONS

0

READS

57

3 authors, including:



**Jok Thikuiy Gang**

Upper Nile University

3 PUBLICATIONS 3 CITATIONS

SEE PROFILE



**Garang Dakjur Lueth**

Juba National University (Juba City)

5 PUBLICATIONS 48 CITATIONS

SEE PROFILE

# Double uterus in young women delivered by Caesarean Section: five cases from South Sudan and Ethiopia

Jok Thikiuy Gang<sup>1</sup>, Garang Dakjur Lueth<sup>2</sup> and Onwar Otien Jwodh<sup>1</sup>

1. Assistant Professor of Obstetrics and Gynaecology, Upper Nile University.
2. Assistant Professor of Obstetrics and Gynaecology, University of Juba.

**Correspondence:**

Jok Thikiuy Gang

ganglual2016@gmail.com

Submitted: September 2021

Accepted: December 2021

Published: February 2022

**Citation:** Gang et al. Double uterus in young women delivered by Caesarean Section: five cases from South Sudan and Ethiopia. South Sudan Medical Journal 2022;15(1):24-28 © 2022 The Author (s)  
**License:** This is an open access article under [CC BY-NC](https://creativecommons.org/licenses/by-nc/4.0/) DOI: <https://dx.doi.org/10.4314/ssmj.v15i1.6>

## ABSTRACT

Double uterus (uterus didelphys) is the second least common congenital anomaly of the female genital tract resulting from failure of fusion of the two Müllerian ducts during embryological development, leading to duplication of the uterus and the cervix. The condition may be associated with abnormalities of the Wolffian duct such as ipsilateral renal agenesis. Presence of a double uterus increases obstetric complications. We report five cases of young women with uterus didelphys who were delivered by Caesarean Section for obstetric indications.

**Key words:** uterus didelphys, double uterus, accessory breast, vaginal septum, case studies, South Sudan, Ethiopia

## INTRODUCTION

Double or didelphys uterus is a congenital anomaly of the female genital tract, arising from failure of fusion of the two Müllerian ducts during embryological development, leading to duplication of the reproductive organs. Although duplication may involve the uterus, cervix, vulva, bladder, urethra, vagina, and anus, it is generally confined to the uterus (uterus didelphys) and cervix (bicollis).<sup>[1]</sup>

Review of the prevalence of different types of uterine malformations revealed that uterus didelphys was the second least common (8.3%) of all Müllerian duct anomalies after complete agenesis (3%). Septate uterus was found to be the most common (35%).<sup>[2,3]</sup>

Because the Müllerian ducts develop often in association with Wolffian ducts, abnormalities of the kidneys may be found in conjunction with uterine abnormalities.<sup>[4,5]</sup> Ipsilateral renal agenesis where one kidney does not develop is associated with 15 to 20% of cases of double uterus. These anomalies are found on the right in 65% of patients.<sup>[1,6,7]</sup> Longitudinal vaginal septum and a blind hemivagina are found in up to 15 - 30% of patients with double uterus.<sup>[6]</sup>

Most women with uterus didelphys are asymptomatic.<sup>[8]</sup> However, in the presence of varying degrees of longitudinal vaginal septum, some patients may present with dyspareunia or dysmenorrhoea. A thick septum may hinder sexual intercourse or vaginal delivery.<sup>[9]</sup> Genital neoplasms, haematocolpos and haematometocolpos where menstrual blood collects behind an obstruction are rarely reported in association with uterus didelphys.<sup>[9]</sup> Despite some of these complications, there are many cases of women with a uterus didelphys who do not exhibit any reproductive or pregnancy related challenges.

## CASE DESCRIPTIONS

### Case 1.

A 24-year-old primigravida lady (Ethiopian national) whose gestational age (GA) was 34 weeks and 3 days from reliable dates supported by early second trimester

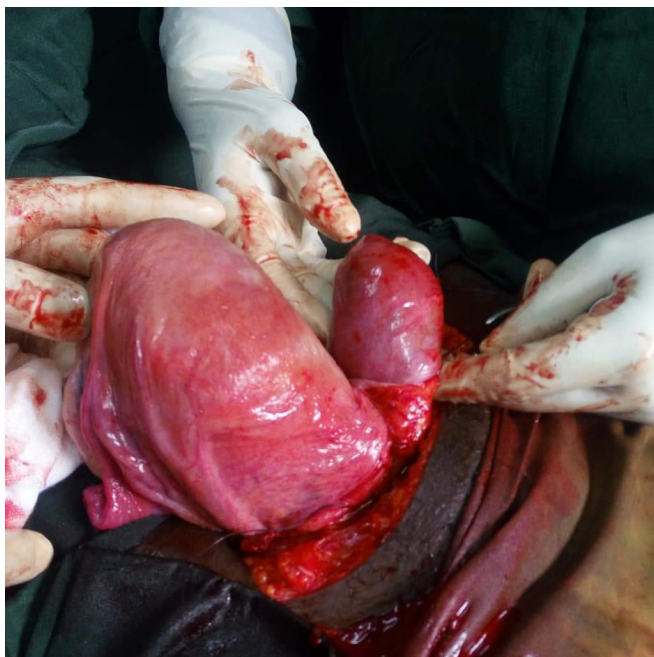


Figure 1. Case 1. Double uterus – anterior view

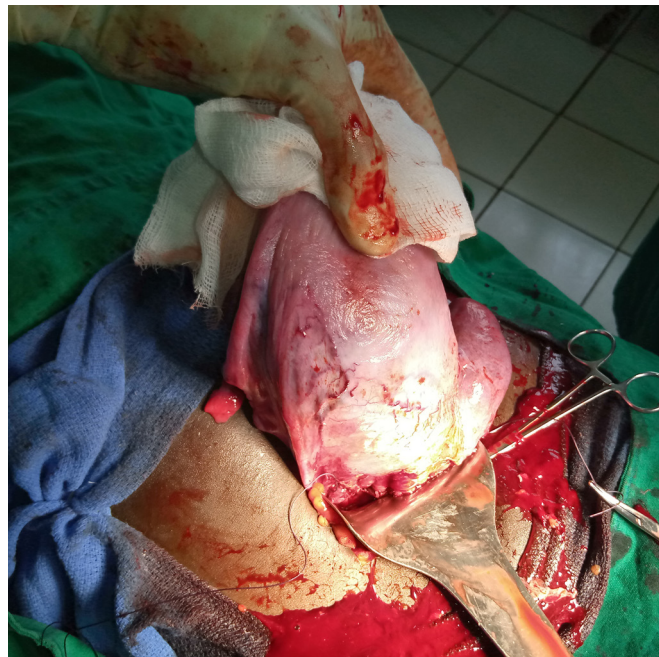

Figure 2. Case 2. Double uterus – anterior view

ultrasound. She had one antenatal clinic (ANC) visit at a nearby health centre where ultrasound scan was done. She was referred on February 8th 2019 to Ras Desta Damtew Memorial Hospital, Addis Ababa, Ethiopia following presentation to the health centre with “pushing down” pain and vaginal bleeding for two hours.

On arrival she was still bleeding. Her general condition was stable. BP 100/70 mm Hg, PR 112 bpm, RR 18 breath/minute. Fundal height was 32 weeks, longitudinal lie, cephalic presentation. She had two to three moderate contractions every 10 minutes. Pelvic examination was deferred. Ultrasound examination showed a single intrauterine pregnancy, cephalic presentation, placenta anterior covering the internal cervical os, average GA of 35 weeks and estimated fetal weight (EFW) of 2.6 kg and single deepest pocket (SDP) of 2.4 cm. Blood group was O+ve, haematocrit 34 %.

She was admitted as a case of placenta praevia with ongoing bleeding in labour. Caesarean Section was successfully done under aseptic conditions and general anaesthesia. A male child was delivered weighing 2.5 kg with Apgar scores of 7 and 9 in the 1st and 5th minutes respectively. No gross congenital anomaly was identified. There were two separate mirror image uteri each with a single ovary and Fallopian tube laterally and separate cervix opening into the vagina. The right uterus was the gravid one. Both kidneys were palpated in their normal positions. No other congenital anomaly was encountered. Postoperative course went smoothly with haematocrit 32%. She was discharged on the 3rd day (Figure1).

## Case 2

A 16-year-old primigravida lady (South Sudanese) whose GA was unknown but she claimed to have had eight months amenorrhoea. She had had no Anti-natal Care(ANC) contact but was referred on May 1st 2021 to Maban County Hospital , South Sudan from a Primary Health Care Centre (PHCC) following presentation with leakage of liquor for two days.

On arrival, her condition was stable. Vital signs were normal. Fundal height was 30 weeks, longitudinal lie, cephalic presentation. Positive fetal heart rate. No uterine contractions. Sterile speculum examination revealed a thick longitudinal vaginal septum. The cervix could not be visualized but there was continuous leakage of clear fluid. Ultrasound showed a single intrauterine pregnancy, cephalic presentation, fundal placenta, estimated GA of 32 weeks, EFW of 1.9 kg and amniotic fluid index (AFI) of 3.1 cm. She was admitted as a case of preterm pre-labour rupture of membranes (PPROM) and started on ampicillin, azithromycin and dexamethasone.

Four days later, she went into labour and Caesarean Section under general anaesthesia was undertaken because of the thick longitudinal vaginal septum. A male neonate weighing 2.1 kg was delivered with Apgar scores of 8 and 9 in the 1st and 5th minutes. Intra-operative findings were two separate, mirror image uteri each with a single ovary and Fallopian tube laterally and separate cervix opening into the vagina. The presence of two cervixes was confirmed through the uterine incision. Pregnancy was



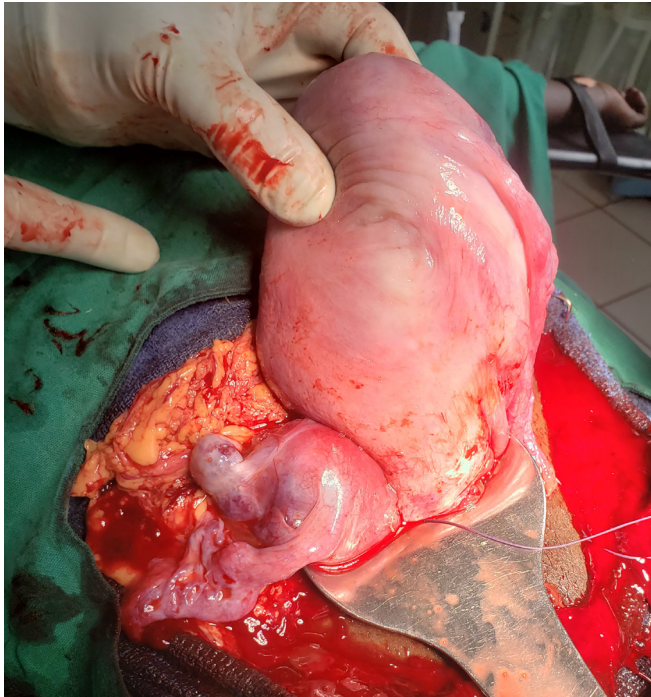


Figure 3. Case 3 – Double uteri – anterior view

in the right uterus. Both kidneys were palpated in their normal positions. No other congenital anomaly identified. She had a smooth postoperative course and discharged on the 3rd postoperative day with haemoglobin of 10.3 g/dl. (Figure 2).

**Case 3**

A 21-year-old primigravida (Sudanese refugee) whose last menstrual period (LMP) was unknown, but she reported amenorrhoea for nine months. She was referred to Maban County Hospital from a PHCC on August 9th 2021 with a diagnosis of breech presentation in labour.

Findings on arrival were a term size uterus, longitudinal lie, breech presentation. Fetal heart rate was 132 - 154 bpm. She had three strong contractions every 10 minutes. Cervix was 80% effaced, 3 cm dilated. Pelvis was clinically adequate. Ultrasound findings were a longitudinal lie of a single fetus in breech presentation. Placenta was fundal, no anomaly seen. EFW of 2.9 kg and GA of 36 weeks. Primary Caesarean Section was done under spinal anaesthesia because of prolonged latent first stage of labour plus breech presentation. A male neonate weighing 2.7 kg was delivered with 8 and 9 Apgar score in the 1st and 5th minute respectively.

Intraoperative findings were two separate uteri each with normal single ovary and Fallopian tube laterally and separate cervix. The left sided uterus was the one carrying pregnancy. Both kidneys were palpated in their normal positions. No other congenital anomaly observed. With smooth postoperative course, she was discharged on 4th postoperative day (Figure 3).

**Case 4**

A 28-year-old G6P5 mother (refugee from Sudan) whose LMP was unknown, but claimed to be nine months amenorrhoeic. Referred to Maban County Hospital from a PHCC on September 9th 2021 with diagnosis of breech presentation in labour. She stated to have had five vaginal deliveries of which two were breech presentation.

Findings on arrival were, term size fundal height, longitudinal lie and breech presentation. She had three contractions every 10 minutes. Fetal heart rate was 134 to 148 bpm. Cervix was fully effaced, and 5 cm dilated. Presentation was footling breech with intact membranes. There was another left lateral short cervix which was closed; no vaginal septum was encountered. There was right axillary accessory breast tissue (Figure 4a).

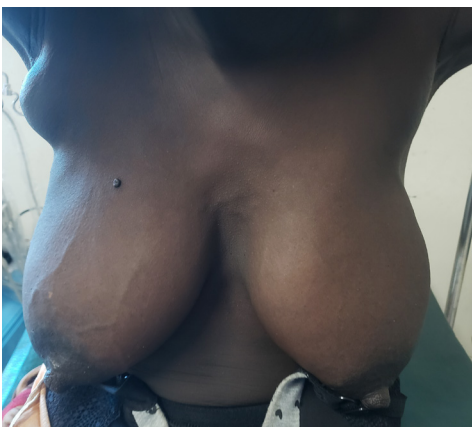


Figure 4a. Accessory breast.

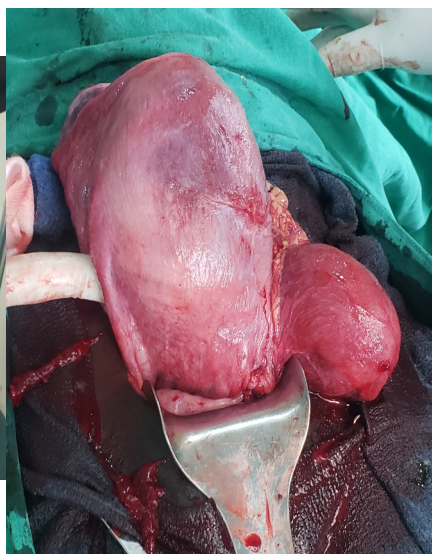


Figure 4b. Anterior view of two uteri.

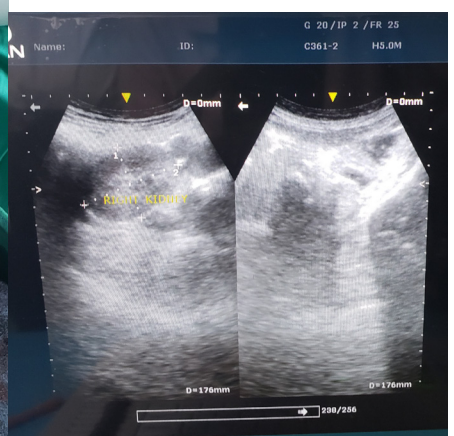


Figure 4c. Absent left kidney on U/S

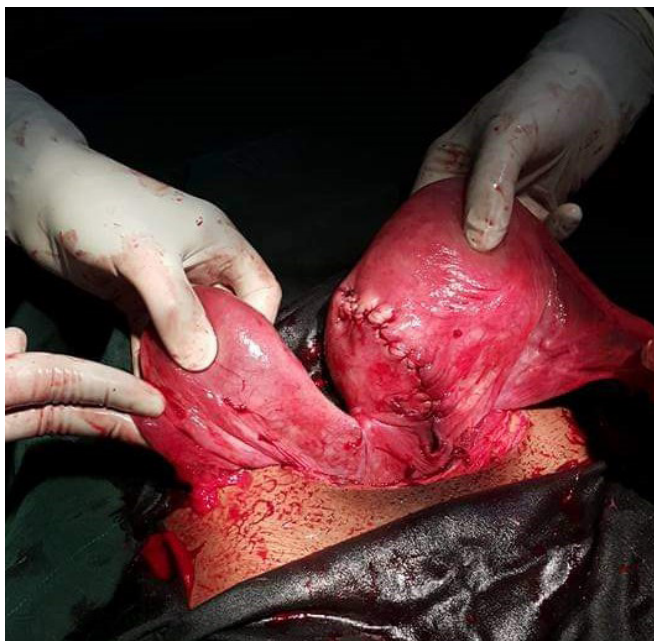

Figure 5. Case 5. Double uterus – anterior view.

Ultrasound showed a single fetus, breech presentation with fundal placenta. No anomaly seen. Gestational age (GA) was 38 weeks and EFW of 3.8 kg. Primary Caesarean Section was undertaken because of the footling breech presentation.

A female neonate weighing 3.7 kg was delivered with Apgar scores of 8 and 9 in the 1st and 5th minute. Intraoperative findings were two separate mirror images uteri (Figure 4b) each with healthy single ovary and Fallopian tube laterally and a separate cervix. The right uterus was the gravid one. Right kidney was palpable in its normal position. The left kidney was absent on palpation (this was confirmed by ultrasound postoperatively- see Figure 4c). No other congenital anomaly was encountered. Postoperative course was uneventful and so was discharged on the 3rd day.

### Case 5

A 25-year-old G2P1 mother (Ethiopian national) whose GA was 38 weeks + 6 days from reliable LMP. She was referred on the 16th of May 2017 from a nearby health facility to Mekelle Hospital, Northern Ethiopia with the diagnosis of transverse lie at term. She had a history of preterm vaginal breech delivery. She was first seen at the regular Out-patient Department on arrival.

Physical examination revealed normal vital signs. Abdomen was 34 weeks size fundal height, transverse lie and FHR 126 to 152 bpm. No uterine contractions. Pelvic examination was deferred. Ultrasound showed a single intrauterine pregnancy at 37 weeks + 3 days, transverse lie (back down) and EFW of 3 kg. The placenta was 1.3

cm away from the internal cervical os. No fetal anomaly detected.

With the diagnosis of low-lying placenta and transverse lie at term, she was admitted to the Maternity suite for elective Caesarean Section. A day later, after informed written consent, Caesarean Section was done under aseptic technique and spinal anaesthesia, through Pfannenstiel and lower uterine segment transverse incisions. A male neonate weighing 2.8 kg was delivered with Apgar scores of 8 & 9 in the 1st and 5th minutes. Intraoperative findings were two uteri with pregnancy in the left uterus. Both kidneys were palpated and found to be in their normal positions with no malformations. After abdominal closure, vaginal examination was done and she was found to have two cervixes. Postoperative course was smooth and she was counselled on the diagnosis, possible abnormal lies or presentation in her subsequent pregnancies and discharged on day three (Figure: 5).

### DISCUSSION

Didelphic or double uterus as one of the rare congenital anomalies of the female genital tract<sup>[2,3]</sup> is associated with some Wolffian duct malformations<sup>[4,5]</sup> and therefore should be suspected and investigated in young patients who present with primary amenorrhoea secondary to menstrual outflow obstruction or in a patient diagnosed with vaginal septum, unilateral renal agenesis or in a patient for which two cervixes visualized on speculum examination. Investigations include pelvic ultrasonography, hysteroscopy and MRI.<sup>[10]</sup>

Although infertility and poor pregnancy outcomes have been reported in association with double uterus,<sup>[5,9,11,12]</sup> many cases have been reported to have successful pregnancy outcomes with no history of fertility impairment.<sup>[4,8]</sup> A long term retrospective follow-up of 49 women with uterus didelphys found no impairment with fertility and decreased rate of spontaneous abortion; however the rate of prematurity was increased in comparison to other studies on septate and bicornuate uteri.<sup>[4]</sup> All of our five cases in this series denied any fertility concern, although each had obstetric complications, but with favourable outcomes.

Cases of simultaneous twin pregnancies with each fetus in separate uterine horns have been reported.<sup>[13,14]</sup> Except for patients who have history of infertility, cyclic pelvic pain or obstetric complications such as recurrent pregnancy loss and preterm deliveries, surgical corrections (metroplasty) are not indicated in patients diagnosed with uterine didelphys.<sup>[15,16]</sup>

Unless indicated, uterus didelphys by itself is not an indication for Caesarean delivery, although its presence increases rates of Caesarean Section.<sup>[5,10]</sup> All five cases



we report underwent Caesarean Section as indicated by obstetric complications (placenta praevia for the 1st case and malpresentation associated with labour dystocia and with footling breech in the 3rd and 4th cases respectively), transverse lie associated with low lying placenta in the 5th case and presence of thick inelastic vaginal septum for the 2nd case.

### CONCLUSION

The presence of uterus didelphys does not commonly affect fertility rate. However, it does increase pregnancy complications such as preterm delivery, fetal malpresentation and placenta praevia, which in turn increase rates of Caesarean Section delivery. Furthermore, pregnancy occurs in either uterus. While double uterus is associated with ipsilateral renal agenesis and longitudinal vaginal septum, we have not found a previous report of an association with accessory breast (polymastia). However, it is quite common and so may not be directly related.

The purpose of this case series is to share lessons learned in clinical practice, as these lessons may help clinicians in designing antenatal care and labour follow-up policy for patients diagnosed with double uterus.

**Conflict of Interests:** None

**Acknowledgment:** We're grateful to the operation theatre staff of Maban County Hospital (South Sudan), Ras Desta Damtew Memorial Hospital (Ethiopia) and Mekelle Hospital (Ethiopia) for obtaining photographic records for this case series.

### References

1. Vercellini P, Daguati R, Somigliana E, et al. Asymmetric lateral distribution of obstructed hemivagina and renal agenesis in women with uterus didelphys: institutional case series and a systematic literature review. *Fertil Steril* 2007;87:719. <https://doi.org/10.1016/j.fertnstert.2007.01.173>
2. Grigoris F, Michel C, Basil C, John N, Paul D. Clinical implications of uterine malformations and hysteroscopic treatment results. *Human Reproduction Update* 2001;7(2):161–174.
3. Shadi R, Pameela B, Isamarie L, et al. Didelphys Uterus: A Case Report and Review of the Literature. *Case Reports in Obstetrics and Gynecology* 2015; Article ID 865821, 5 pages. <https://doi.org/10.1155/2015/865821>
4. Heinonen P. Clinical implications of the didelphic uterus: long-term follow-up of 49 cases. *European Journal of Obstetrics & Gynecology and Reproductive Biology* 2000;91(2):183–190.
5. Heinonen P. Uterus didelphys: a report of 26 cases. *European Journal of Obstetrics & Gynecology and Reproductive Biology* 1984;17(5):345–350.
6. Burgis J. Obstructive Mullerian anomalies. case report, diagnosis and management. *Am J Obstet Gynaecol.* 2001;185:338-44.
7. Gruenwald P. Relation of growing Mullerian duct to the Wolffian duct and its importance for the genesis of malformation. *Anat Rec.*;1946;81:1-19. <https://doi.org/10.1002/ar.1090810102>
8. Carrington BM, Hricak H, Nuruddin RN, et al. Mullerian ducts anomalies: MR imaging evaluation. *Radiology.* 1990;176:715-20.
9. Parvin, A., Khan, B., Alam, J., Ruby, F., & Iqbal, T. (2014). Uterine Didelphys Associated with Obstructed Hemivagina and Ipsilateral Renal Anomaly (OHVIRA) Syndrome: a Case Report. *Pulse*, 6(1-2), 66–69. <https://doi.org/10.3329/pulse.v6i1-2.20358>
10. Jena L, Puhan JN, Swain S, Kanungo S. Uterine didelphys: a rare case report. *Int J Reprod Contracept Obstet Gynecol* 2015;4: International Journal of Reproduction, Contraception, Obstetrics and Gynecology 2015 Oct;4(5):1613-1614.
11. Pui M. Imaging diagnosis of congenital uterine malformation. *Computerized medical imaging and graphics* 2004;28(7):425-33.
12. Pedro A. Reproductive performance of women with uterine malformations. *Human Reproduction* 1993; 8(1):122–126.
13. Nohara M, Nakayama M, Masamoto H, et al. Twin pregnancy in each half of a uterus didelphys with a delivery interval of 66 days. *Br J Obstet Gynecol.* 2003;110:331–2
14. Ozgur O, Mert T, Aslihan Y, Aykut O. Spontaneous twin gestation in each horn of uterus didelphys complicated with unilateral preterm labor: Case Reports in Perinatal Medicine 2014;3(1):53-56. <https://doi.org/10.1515/crpm-2013-0061>
15. Paul C, Kunwar P, Stephen N, Steven T. Female genital anomalies affecting reproduction. *Fertil Steril.*2002;78(5):899–915. [https://doi.org/10.1016/S0015-0282\(02\)03368-X](https://doi.org/10.1016/S0015-0282(02)03368-X)
16. Ronald E, Alan H, Marc R. Surgical management of congenital uterine anomalies. In: Rose BD, editor. *UpToDate*. Waltham, MA: UpToDate. Tetracycline Teratology. 2007.